

Gemeinschaftspraxis  
Dr. med. Reinhard Smettan  
Dr. med. Heike Smettan

Fachärzte für Augenheilkunde  
Naturheilverfahren, Umweltmedizin  
Johannesstrasse 31  
D-70806 Kornwestheim  
Tel.: 0049 7154 21020  
Fax: 0049 7154 5813

# ozonetherapy in Ophthalmology

R. Smettan MD

**The challenge :**  
an increase of visual  
deterioration without  
real conventional  
medical help

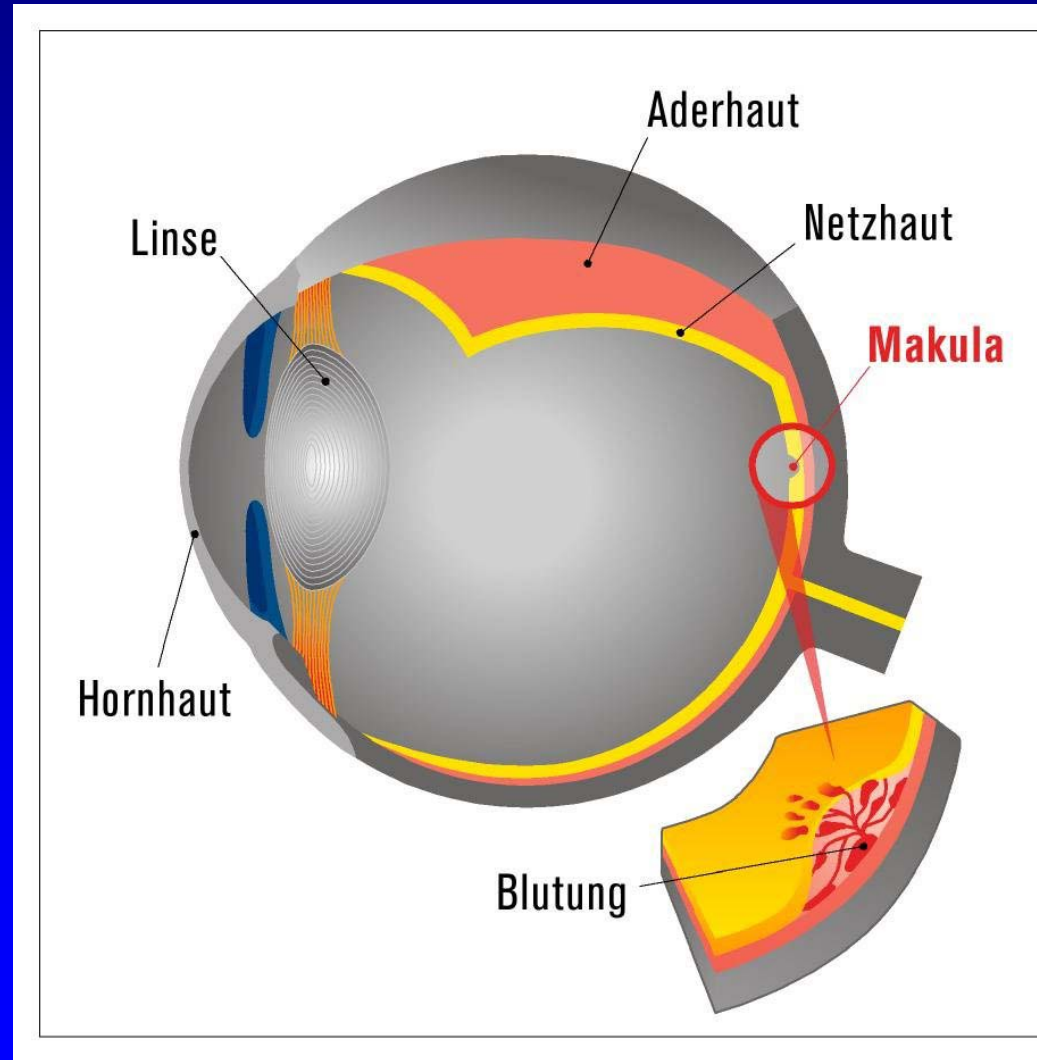
# Anatomy of the eye

## Retina:

Layers of photoreceptor cells at the posterior pole

## Macula:

Area of the best visual perception



# Anatomy of the posterior pole

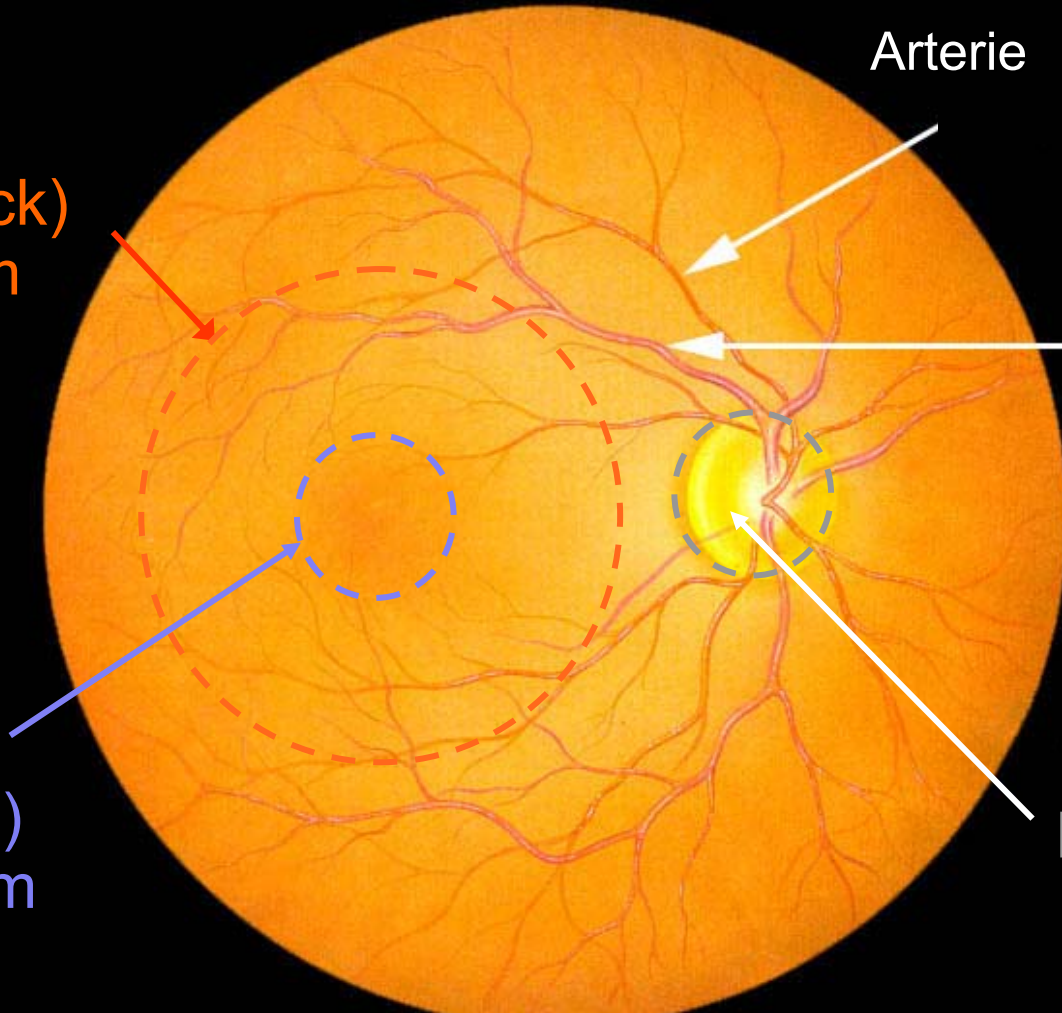
**Makula**  
(=gelber Fleck)  
Ø ca. 5 mm

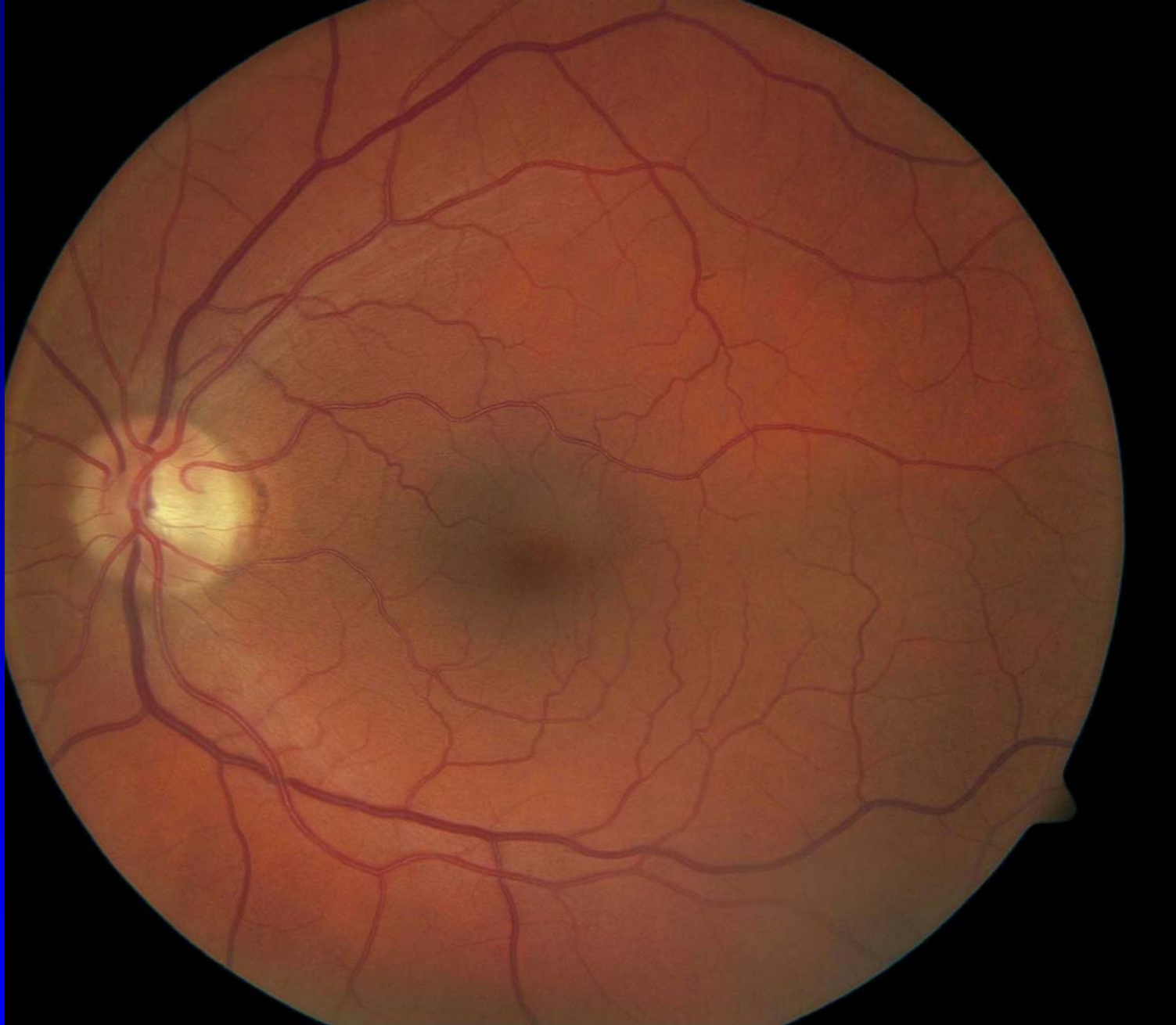
Arterie

Vene

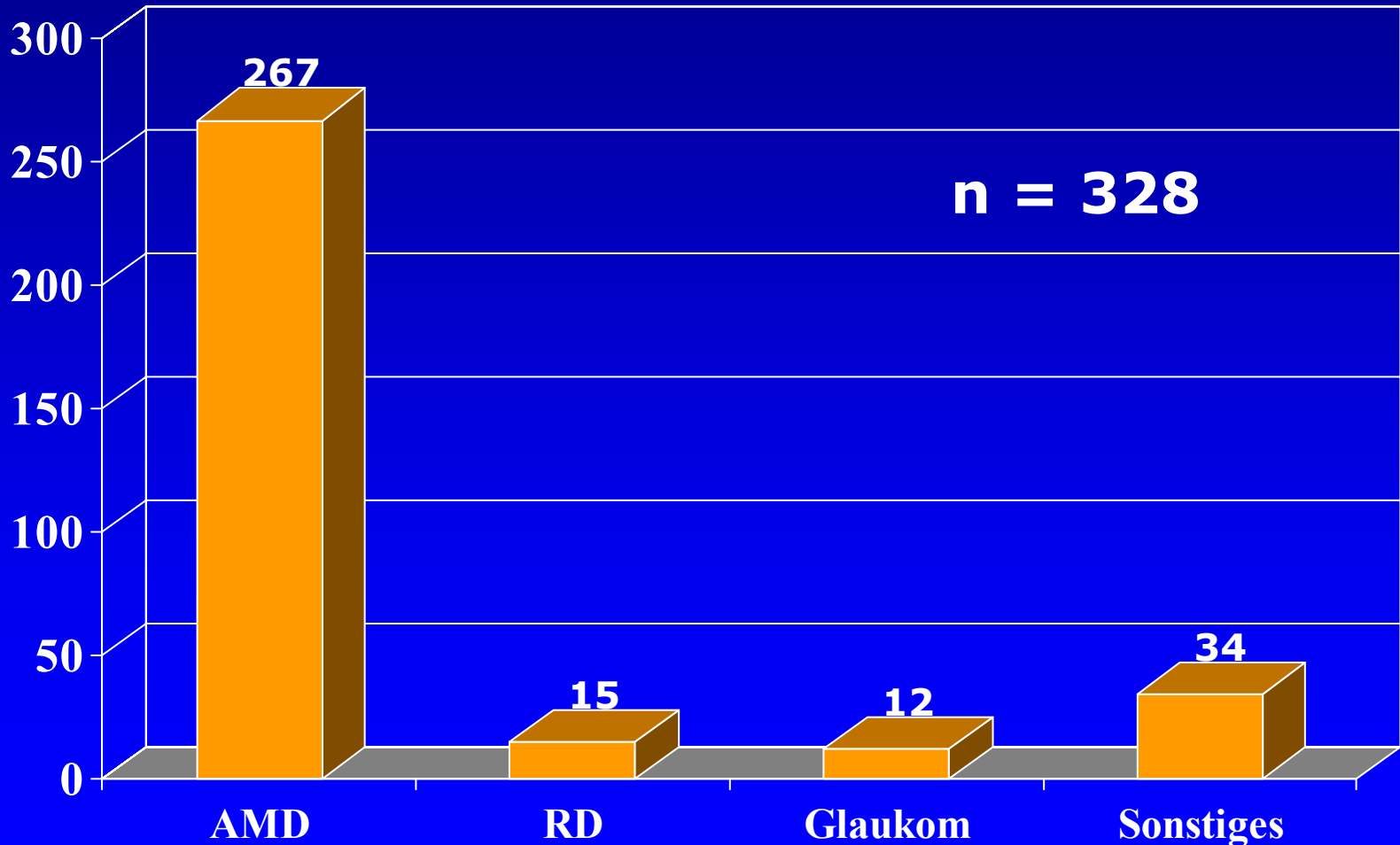
**Fovea**  
(=Sehgrube)  
Ø ca. 1,5 mm

Papille





# Treated illnesses




**Age related macular  
degeneration (AMD)  
is the most common  
cause of blindness!**



# Age related macular degeneration (AMD)

prevention  
identification  
treatment



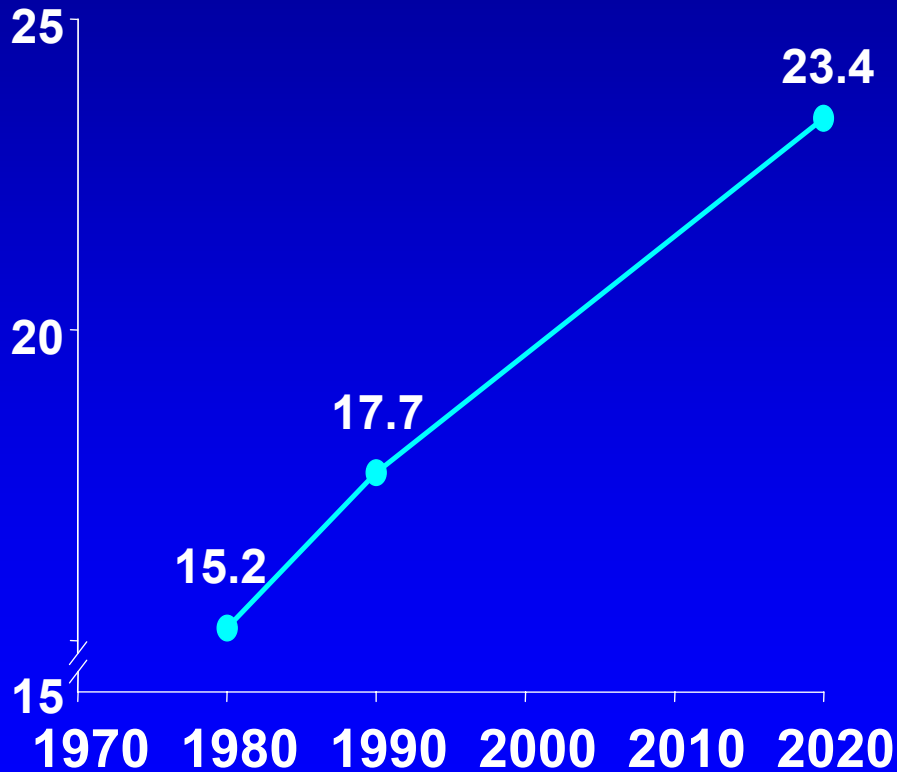
The AMD is with ca. 30 % the leading cause of ophthalmic disease, that leads to severe visual impairment



# AMD

(patients > 65 years of age)

patients > 65 years of age(%)



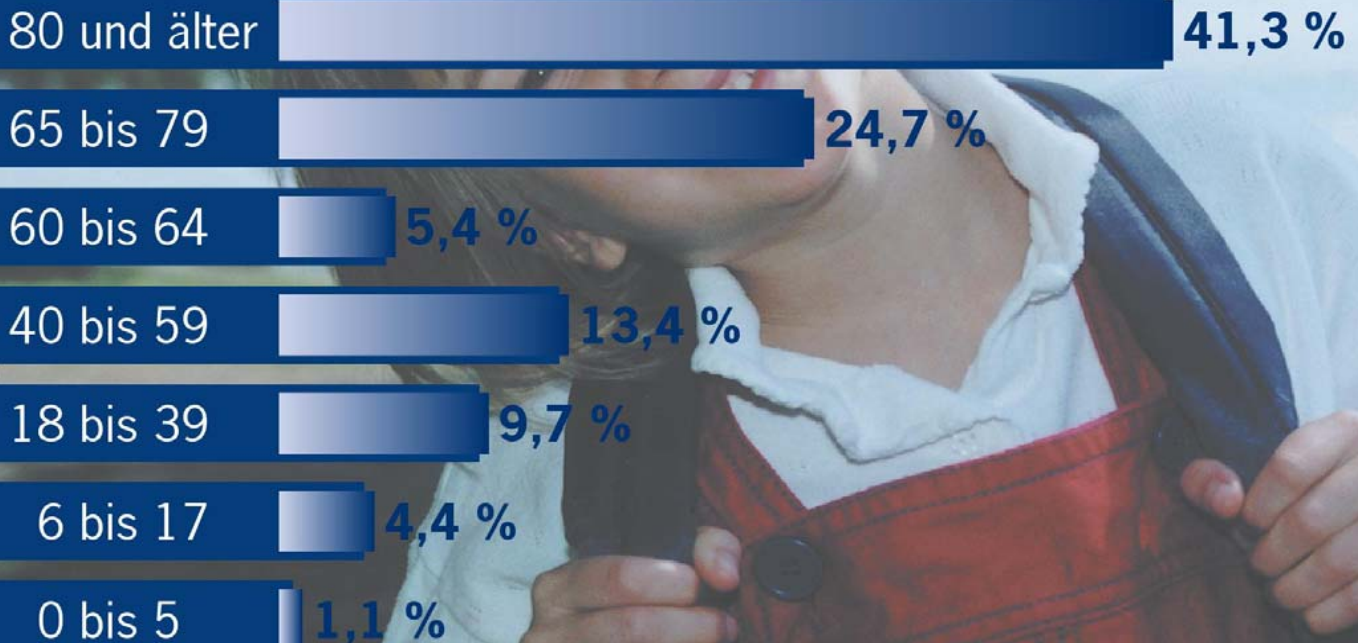
An increasing number of patients are at risk to develop age related macular degeneration

# Risk of severe loss of visual acuity

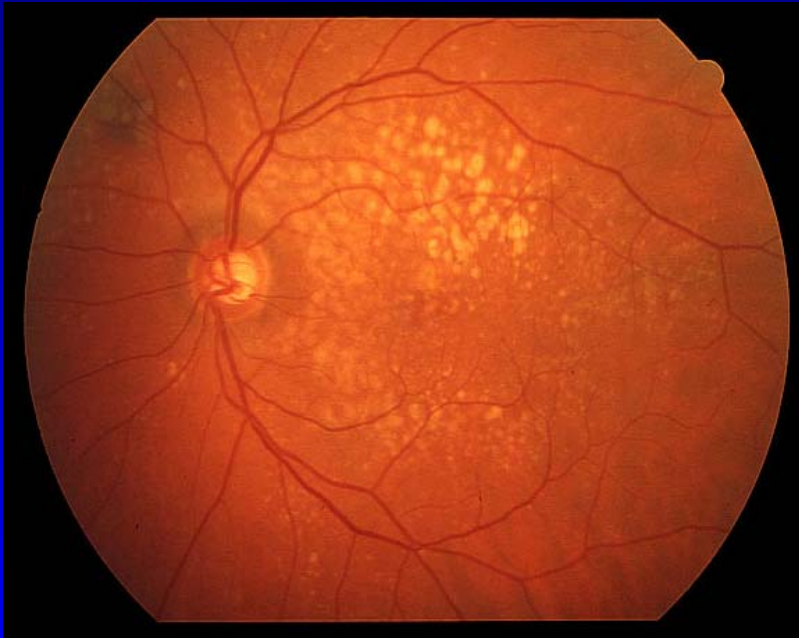## Erblindungsrisiko steigt im Alter sprunghaft an

Zahl der Neuerblindungen in Prozent

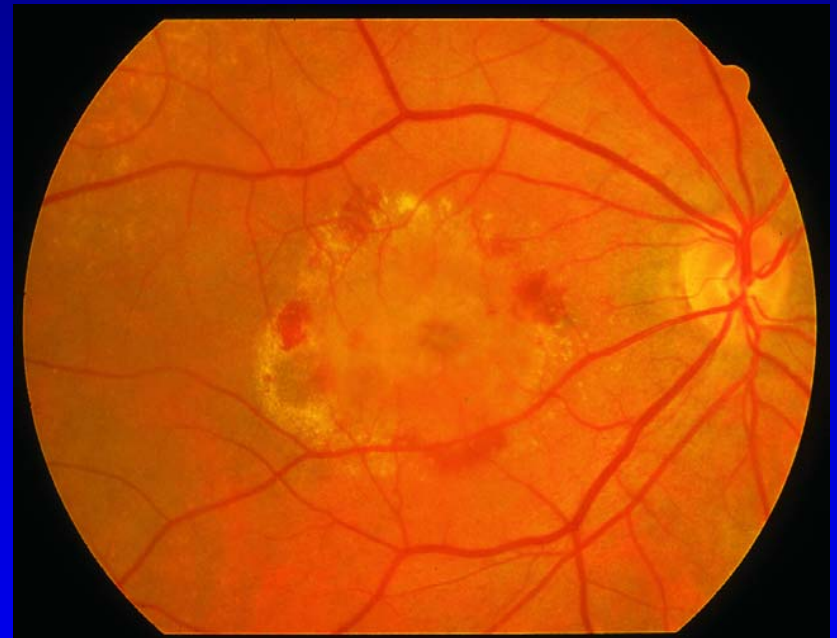in Jahren



# Age related macular degeneration



Non exudative AMD



exudative AMD

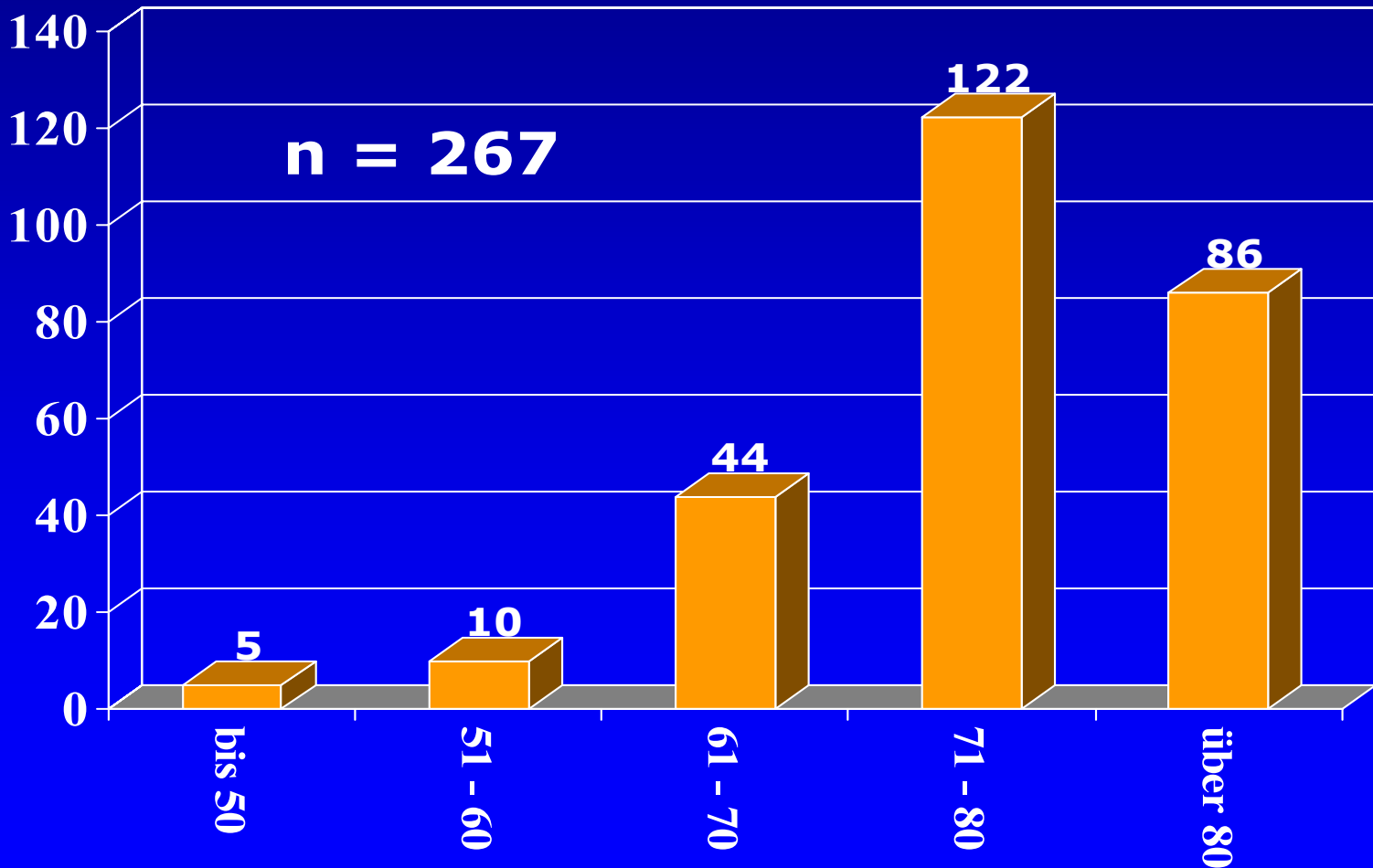
**Usually the  
findings are  
often severe !**

It's high time



Höchste Eisenbahn...

# Distribution in age of AMD





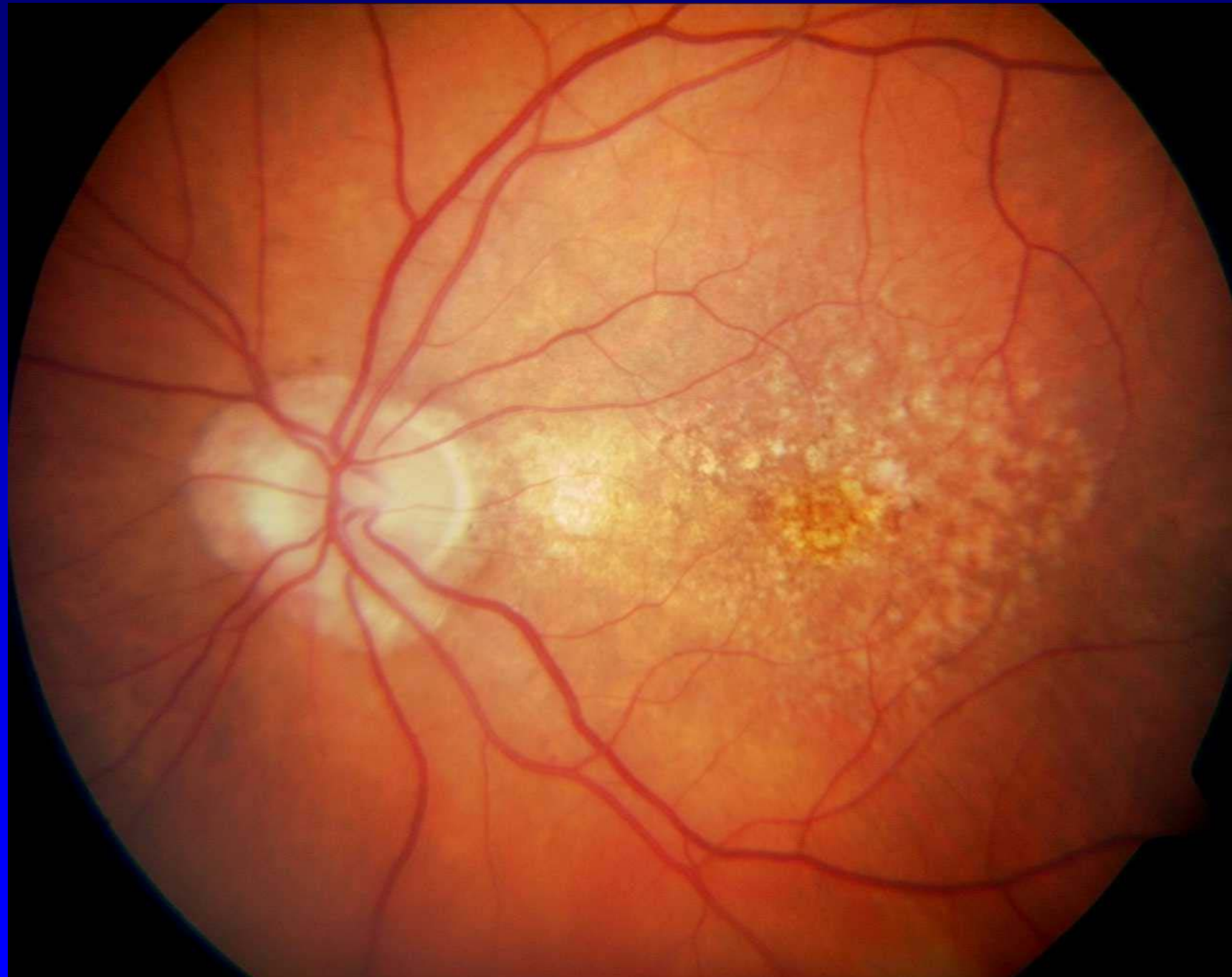# RISK factors of AMD

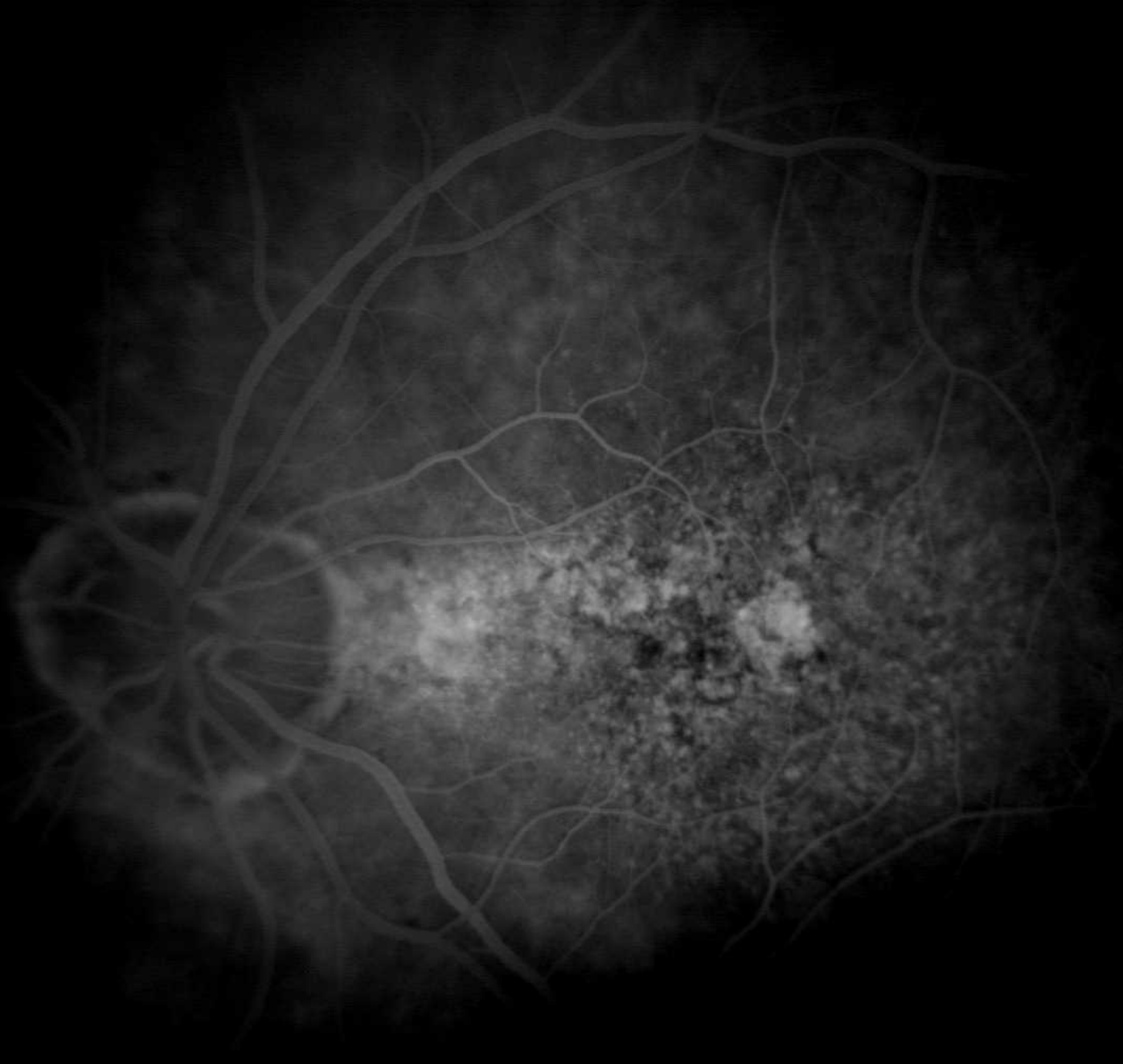
## **proved**

- age
- sex
- smoking
- ophthalmic risks

## **Under study**

- nutrition
- UV-light
- skin colour
- genetic risks
- cardiovascular diseases





# Therapy of the non-exudative AMD

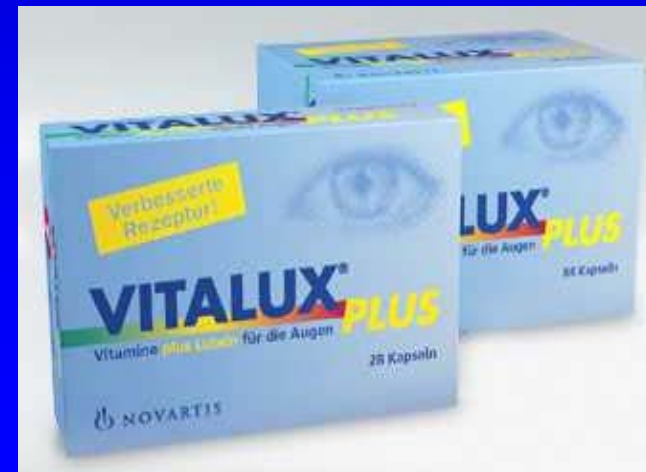prevention:

▶ **healthy + nutrition**, rich of lutein

- **vegetables**
- **fruits**



▶ **Add. nutritions**  
with lutein,  
zinc and copper



# Our choice of treatment of the „dry“ AMD

- ozonetherapy
- Acupunctur
- Add. nutrition  
(z.B. Juice Plus<sup>®</sup> , Vitalux plus<sup>®</sup> u.a.)

# Effect of the ozone therapy

- Stimulation of the erythrocytes
- Stimulation of the immune system
- Increase of the antioxidative capacity of the body
- Improvement of general condition

Dose:

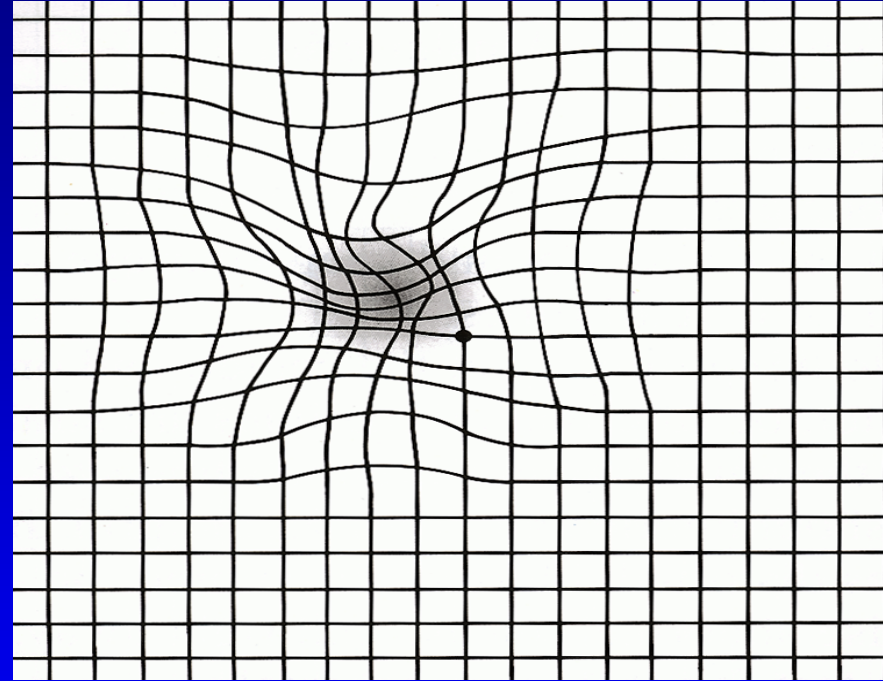
80ml venous blood are  
perfused by 1500 $\mu$ g ozone  
(soluble in 50ml medical  
oxygen)

# AMD

(symptomes of exudative AMD)



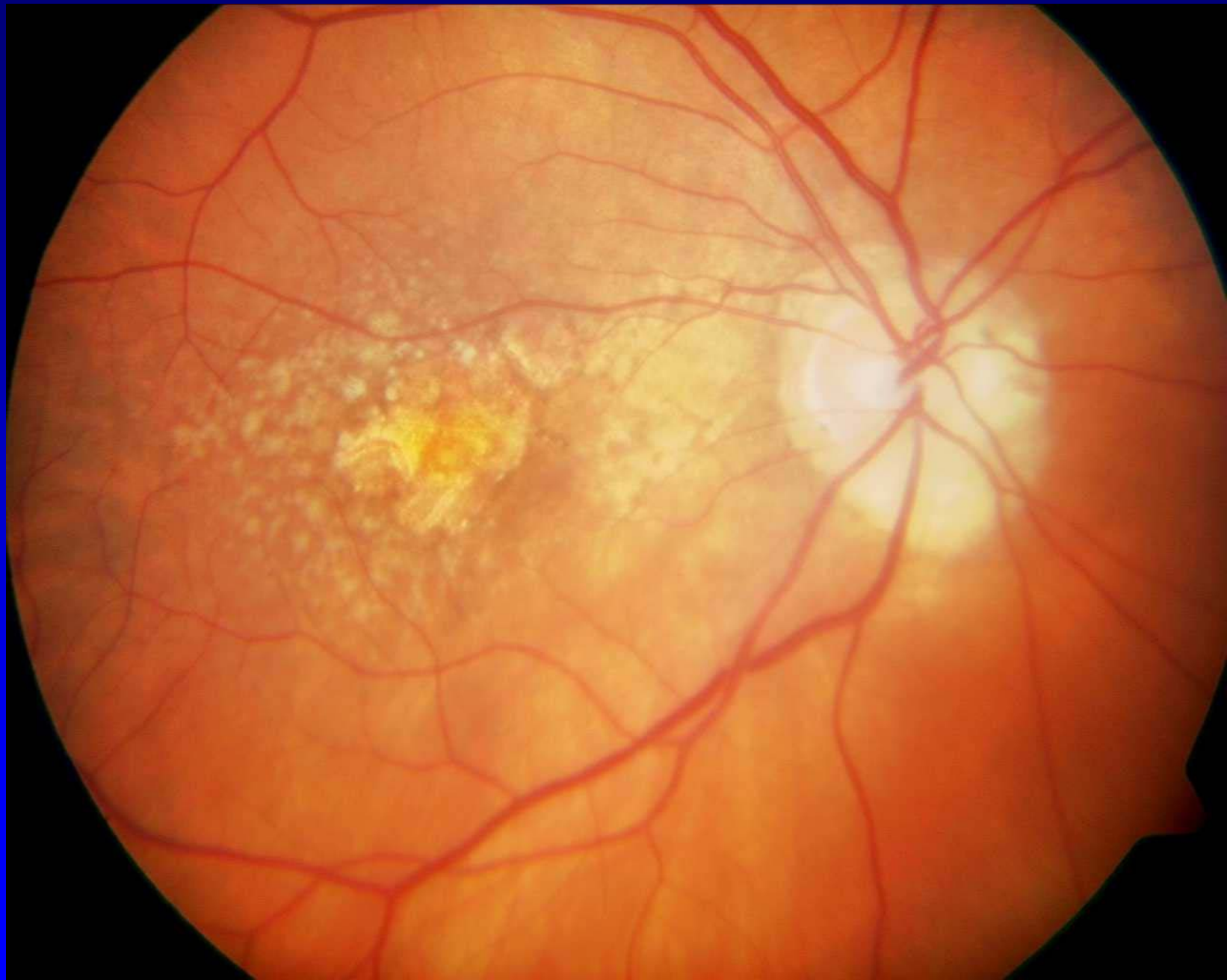
**Central scotoma**  
(grauer Fleck)

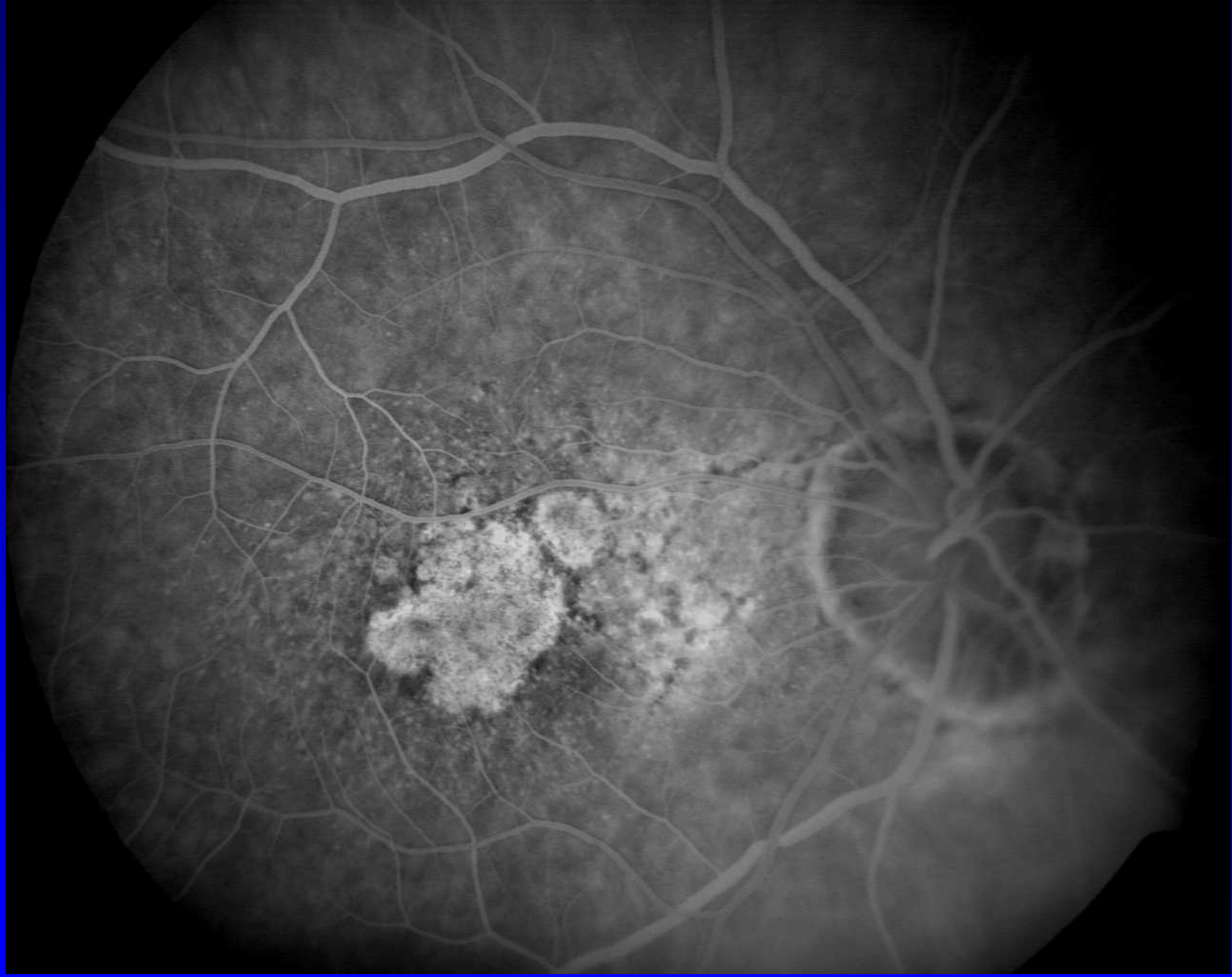


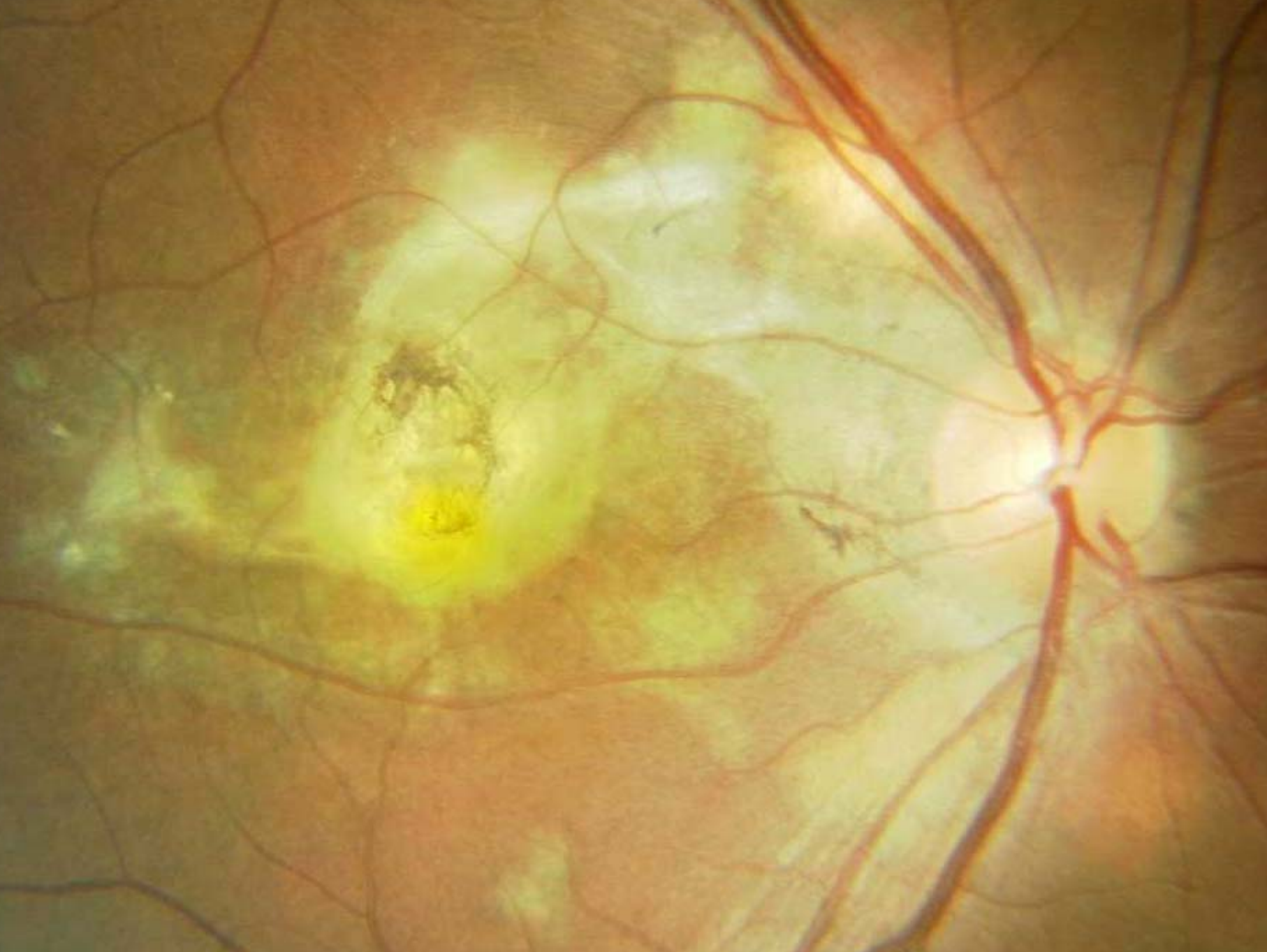**metamorphopsia**  
(Verzerrtsehen)

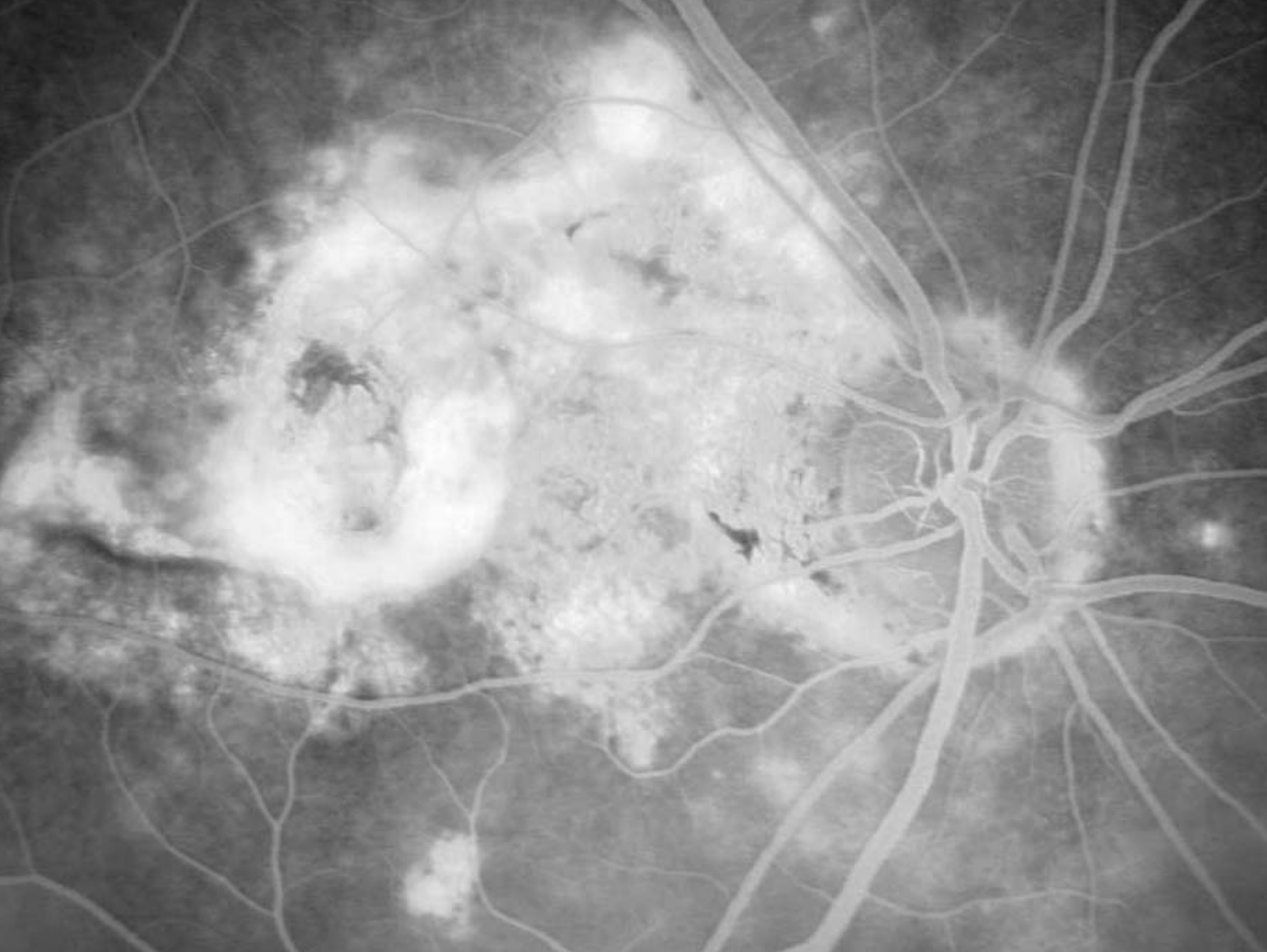
**Main symptoms:** drop of visual acuity



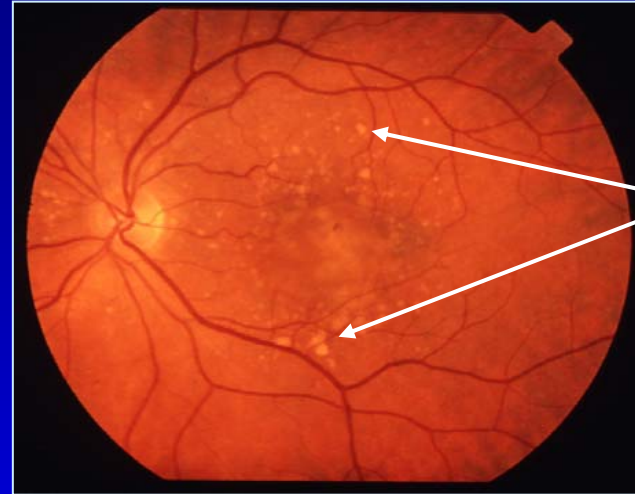
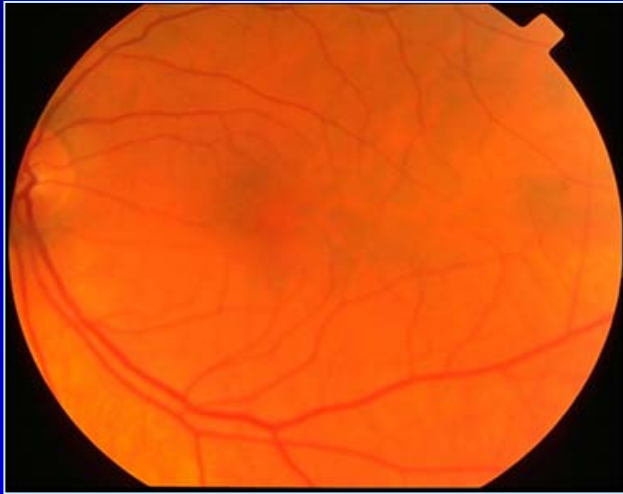







# progression of AMD (Krankheitsverlauf I)



Drusen

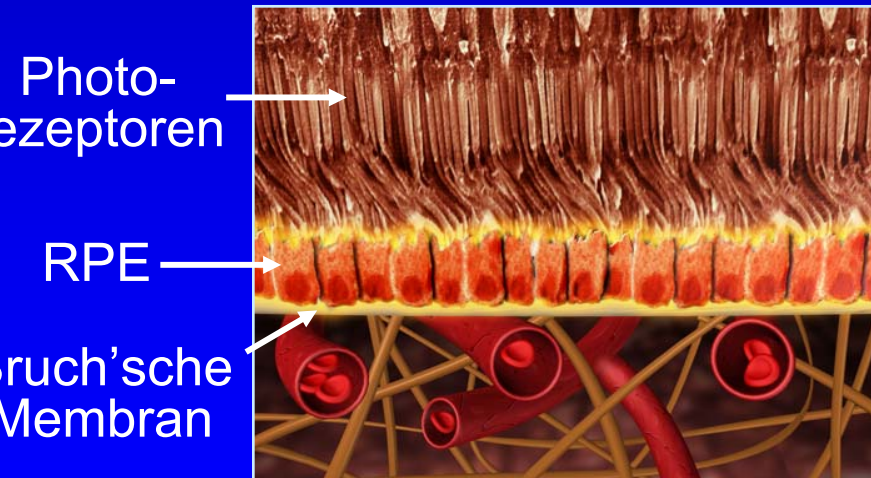
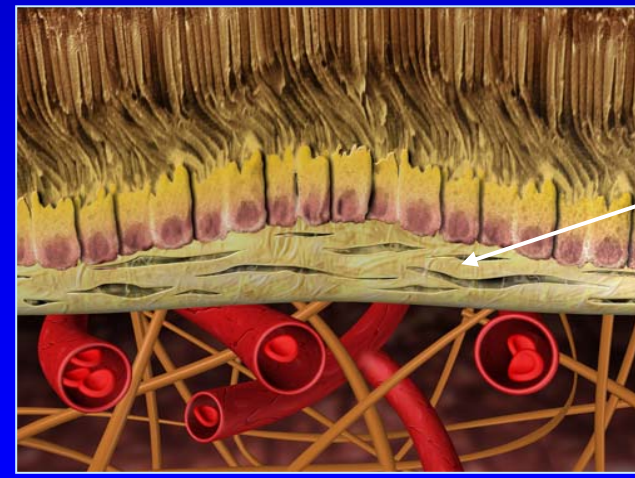


Photo-rezeptoren

RPE

Bruch'sche Membran

Healthy retinal tissue

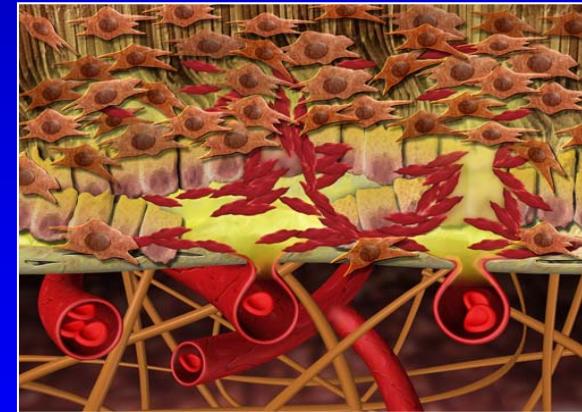
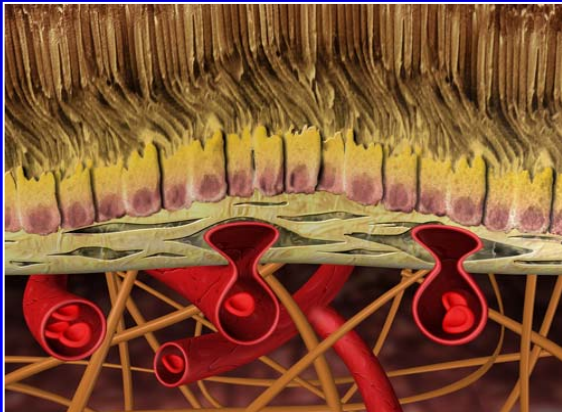
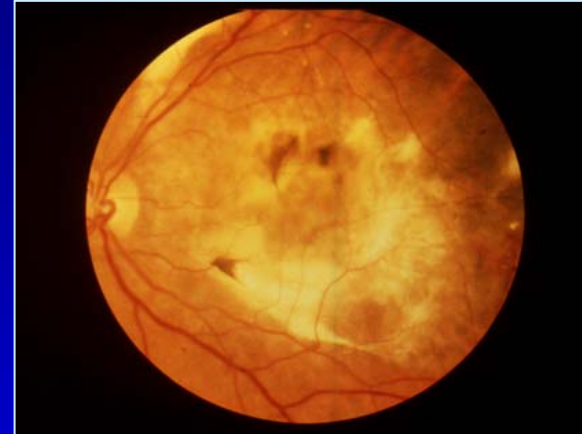
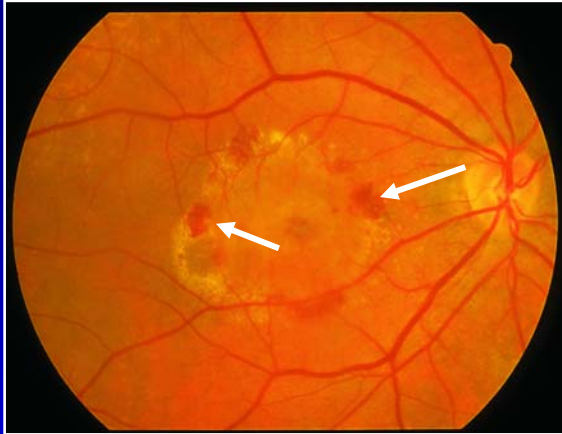


Druse

Swelling of Bruch's membran (drusen)

# progression of AMD

## (Krankheitsverlauf II)



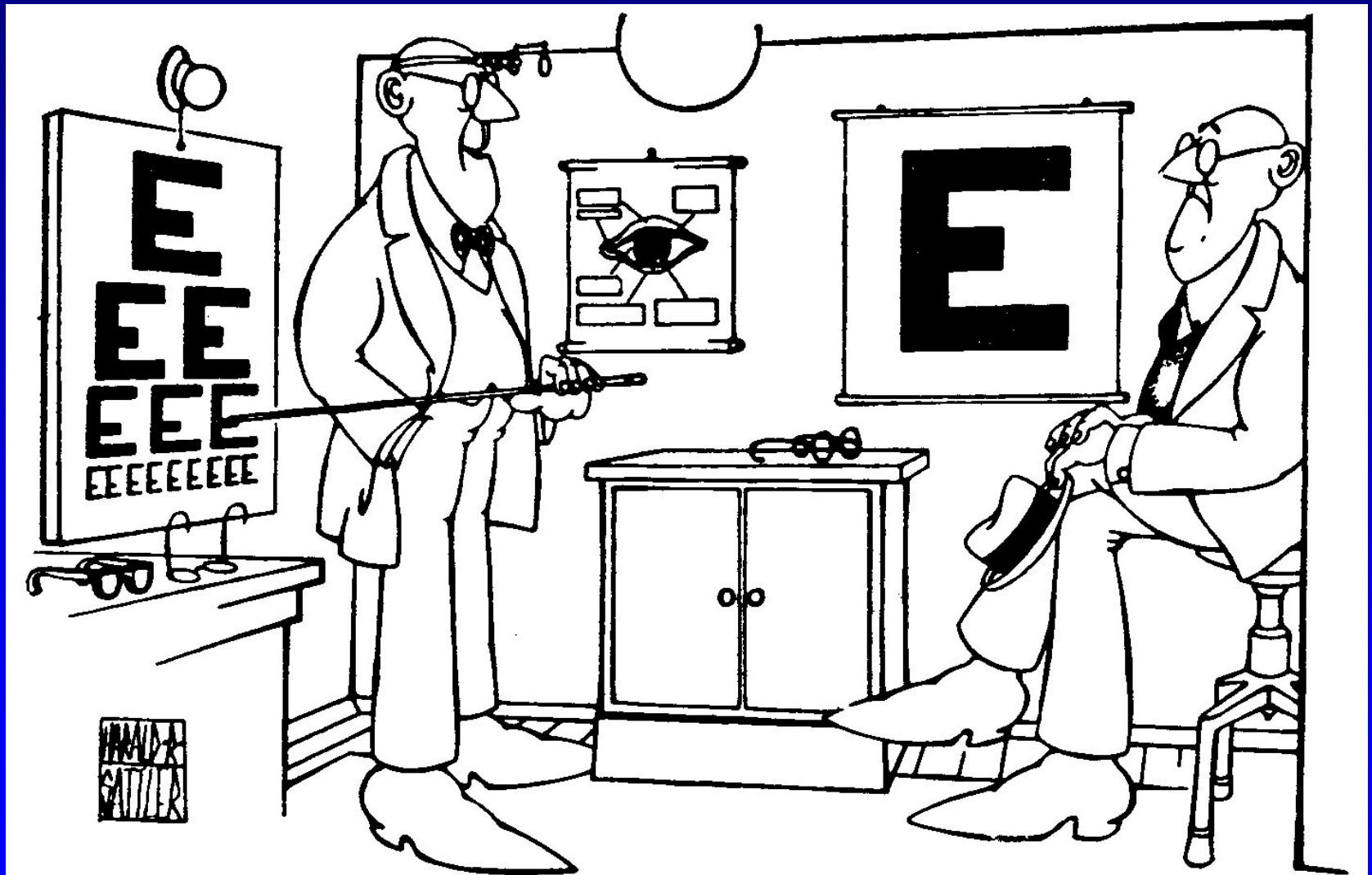
**Abnormal vessels  
penetrating into retinal tissue**

**Terminal stadium  
disciform scar**

# Our choice of treatment of the exudative AMD

- Photodynamic Therapy (PDT)
- ozonetherapy
- Acupunctur
- Add. nutrition  
(z.B. Juice Plus<sup>®</sup> , Vitalux plus<sup>®</sup> u.a.)

Perfect, just read the last line

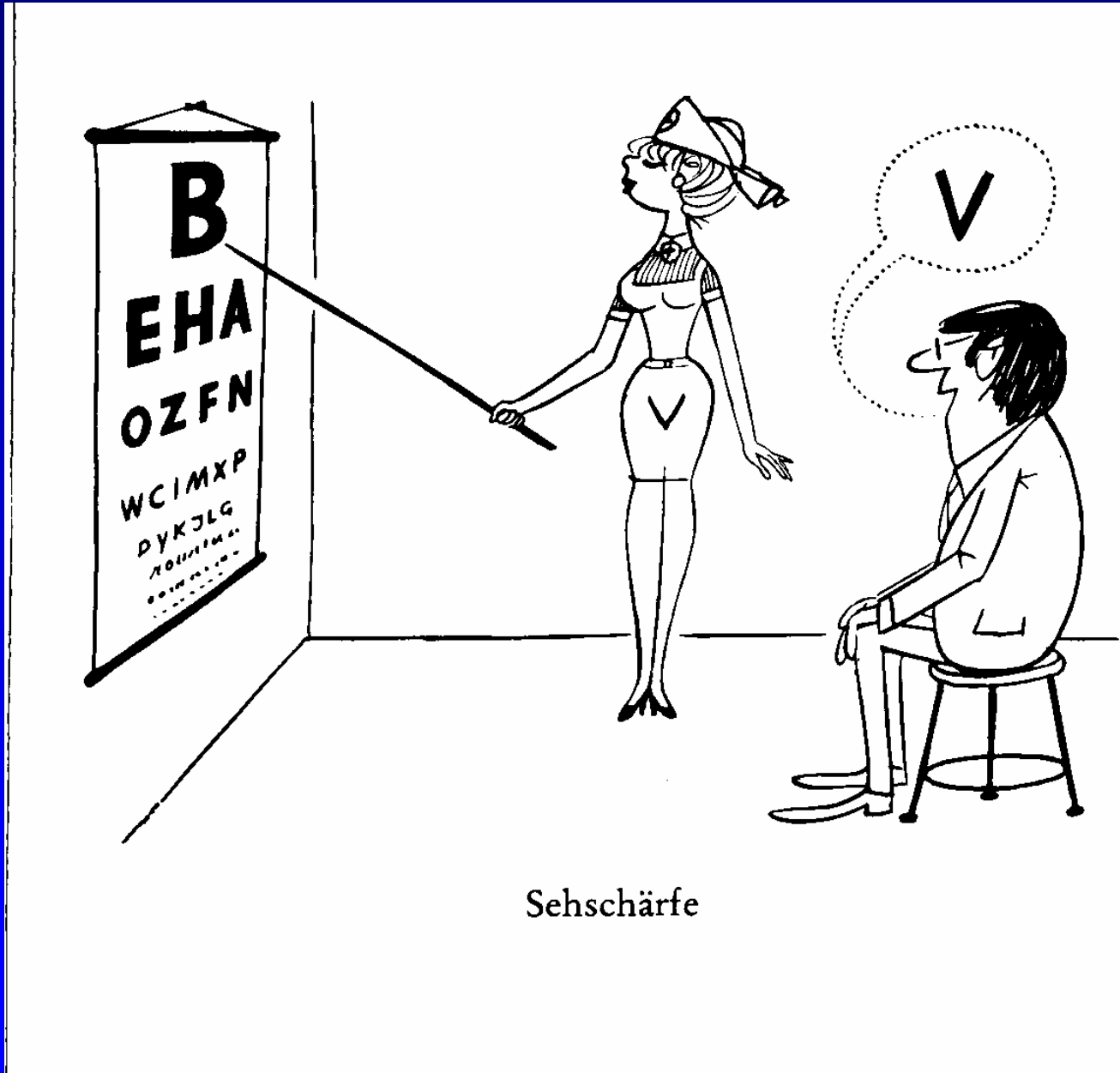


„Fabelhaft! Wieder richtig! Jetzt noch die unterste Zeile.“

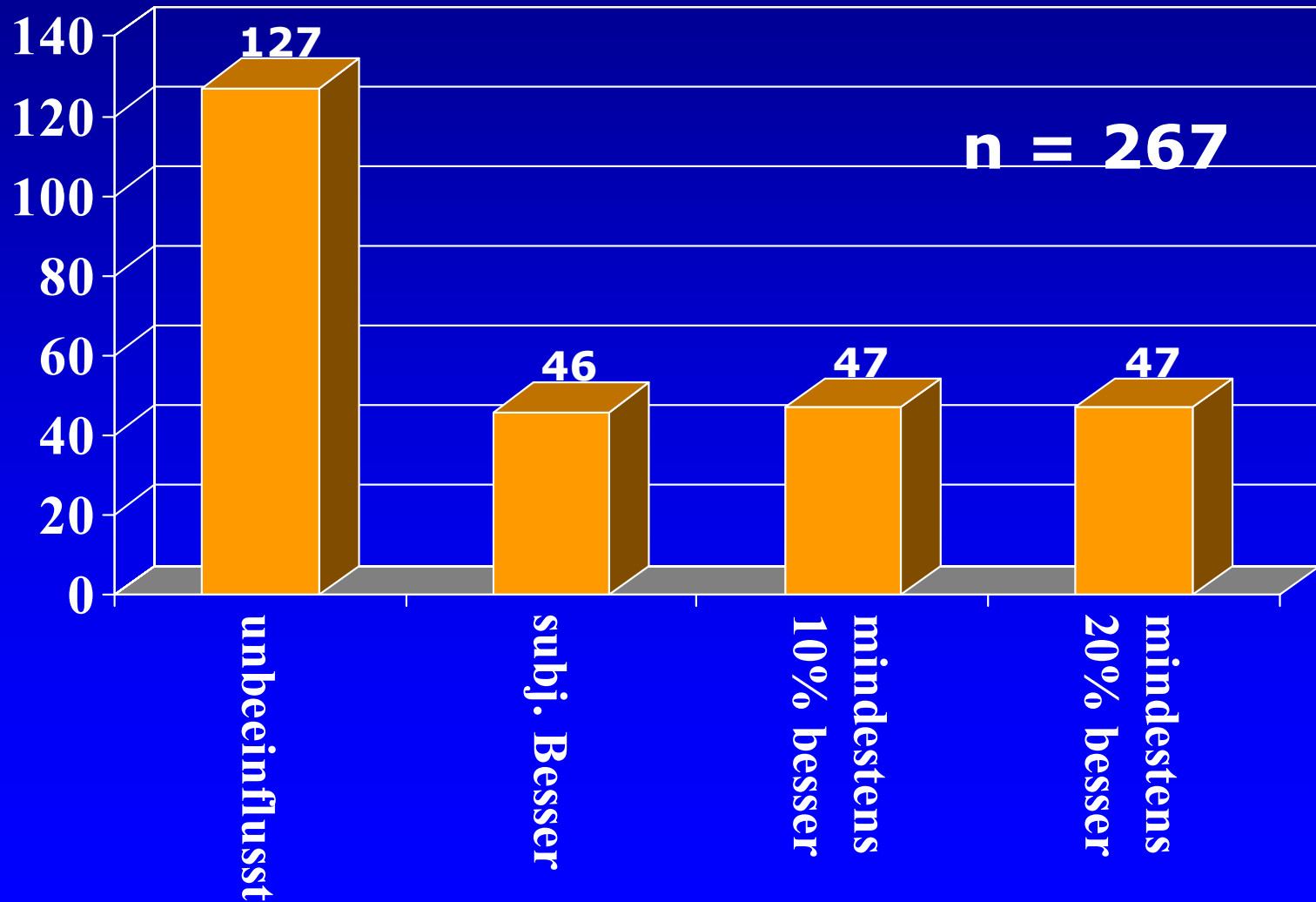
Sattler



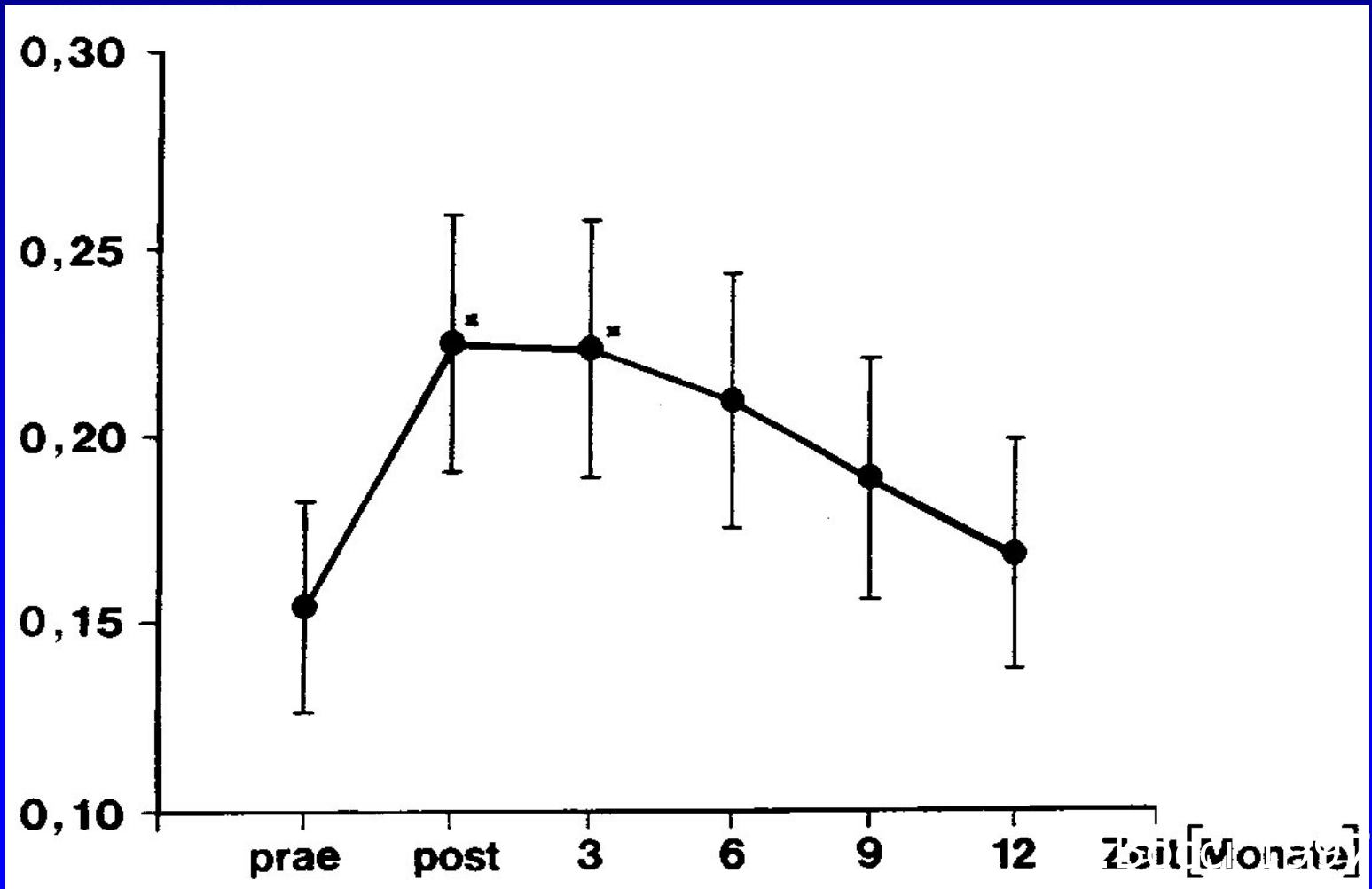
# Visual acuity




# Influence of visual acuity after therapy with AMD



# Progress of visual acuity (Bocci)



Improvement  
of general  
condition



**Stuttgart**

# Fast blind – jetzt sieht Hausfrau wieder klar

Von CATHRIN BACKHAUS

Hausfrau Ursula Riester (57) ist derzeit wohl die glücklichste Stuttgarterin. Wenn sie zum Beispiel in den Spiegel schaut, sieht sie keine schattigen Umrisse, sondern hat ein klares Bild vor sich.

Nach vor ein paar Wochen drohte sie vollends zu erblinden. Die Diagnose der Ärzte: „Senile Makula Degeneration“. Dabei stirbt das Zentrum der Netzhaut ab. Augenarzt Dr. Reinhold Smeltan (52) aus Kornwestheim weiß: „Etwa 40 % aller Deutschen über 60 leiden unter dieser Krankheit.“

Die Stuttgarterin „Ich war verzweifelt und hatte mich schon damit abgefunden, in Zukunft von meinem Mann abhängig zu sein.“

Dann die Rettung: in Zusammenarbeit mit der Deutschen Gesellschaft für Ganzheitliche Augenheilkunde (DGGÄ) wurde eine Behandlungsmethode entwickelt, die der Hausfrau die Sehkraft auf einem Auge rettete – und von 80 auf 100 % verbesserte. Dabei wurde der Patientin Blut abgenommen, mit einem Ozon-Sauerstoff-Gemisch angereichert und zurück in den Körper gespritzt. Der Arzt: „So kann der angereicherte Sauerstoff ins Auge gelangen, sorgt für Durchblutung und Besserung.“

Für Ursula Riester war die Behandlung die einzige Rettung. „Jetzt kann ich wieder ein normales Leben führen und sogar wieder ohne Brille Autofahren, Lesen und Tennis spielen.“

Übrigens: Am 27. Februar tagt die DGGÄ von 14 bis 17.30 Uhr im Hotel am Schloßgarten.



# Pat. Ursula R., geb. 1941

- RE exudative AMD 1995
- RE Argonlaser 1995
- Autumn 1996: LE AMD change to exudative form  
visual acuity changes from 20/20 to 20/30
- December 1996: start of the ozone-Therapy
- After 10 sessions: LE visual acuity improves from 20/30 to 20/ 20 (20/15)
- till today regular sessions (ca. 70x),
- vis. acuity: RE 20/200; LE 20/20 – 20/15

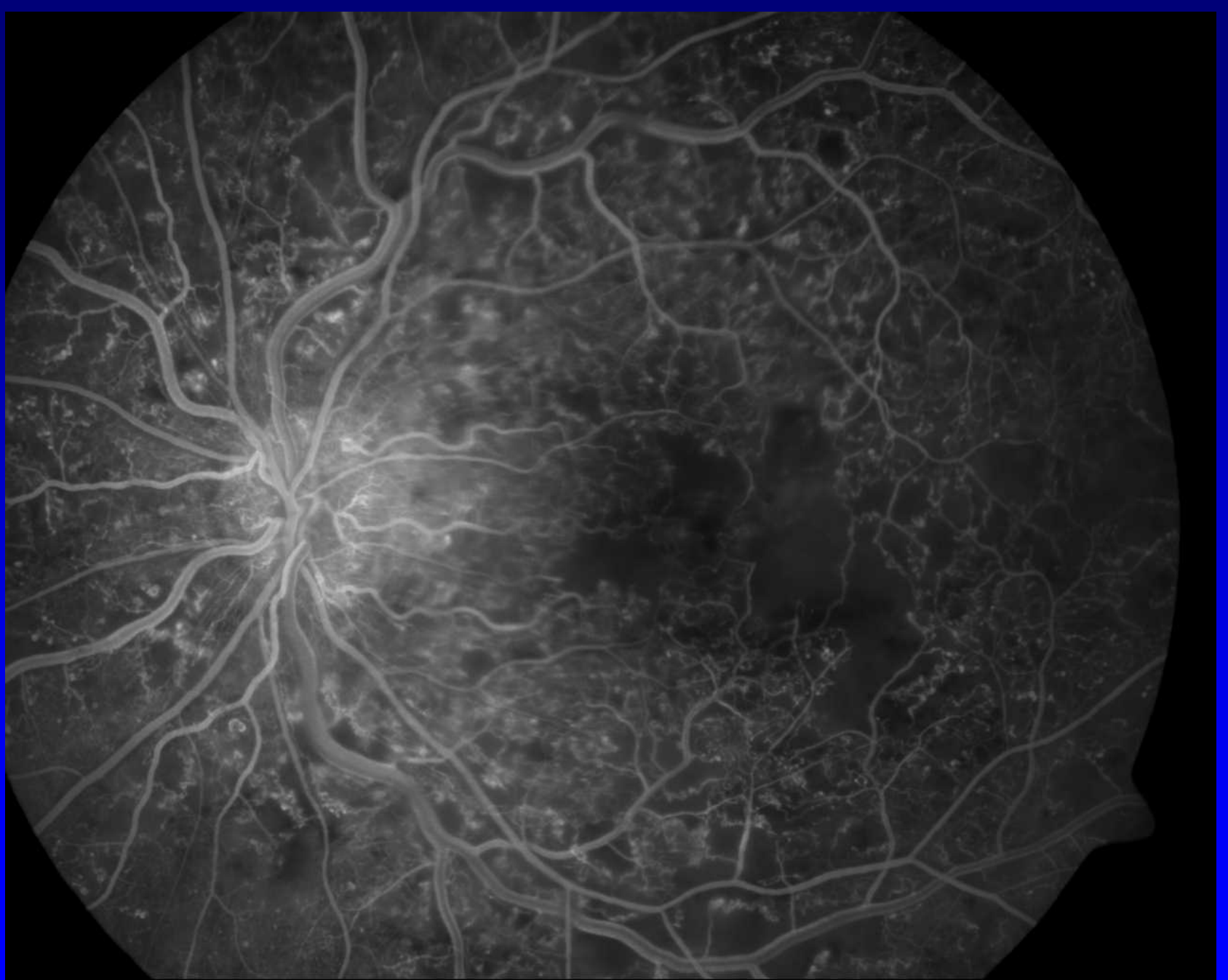
# Pat. Seher M., geb. 1973

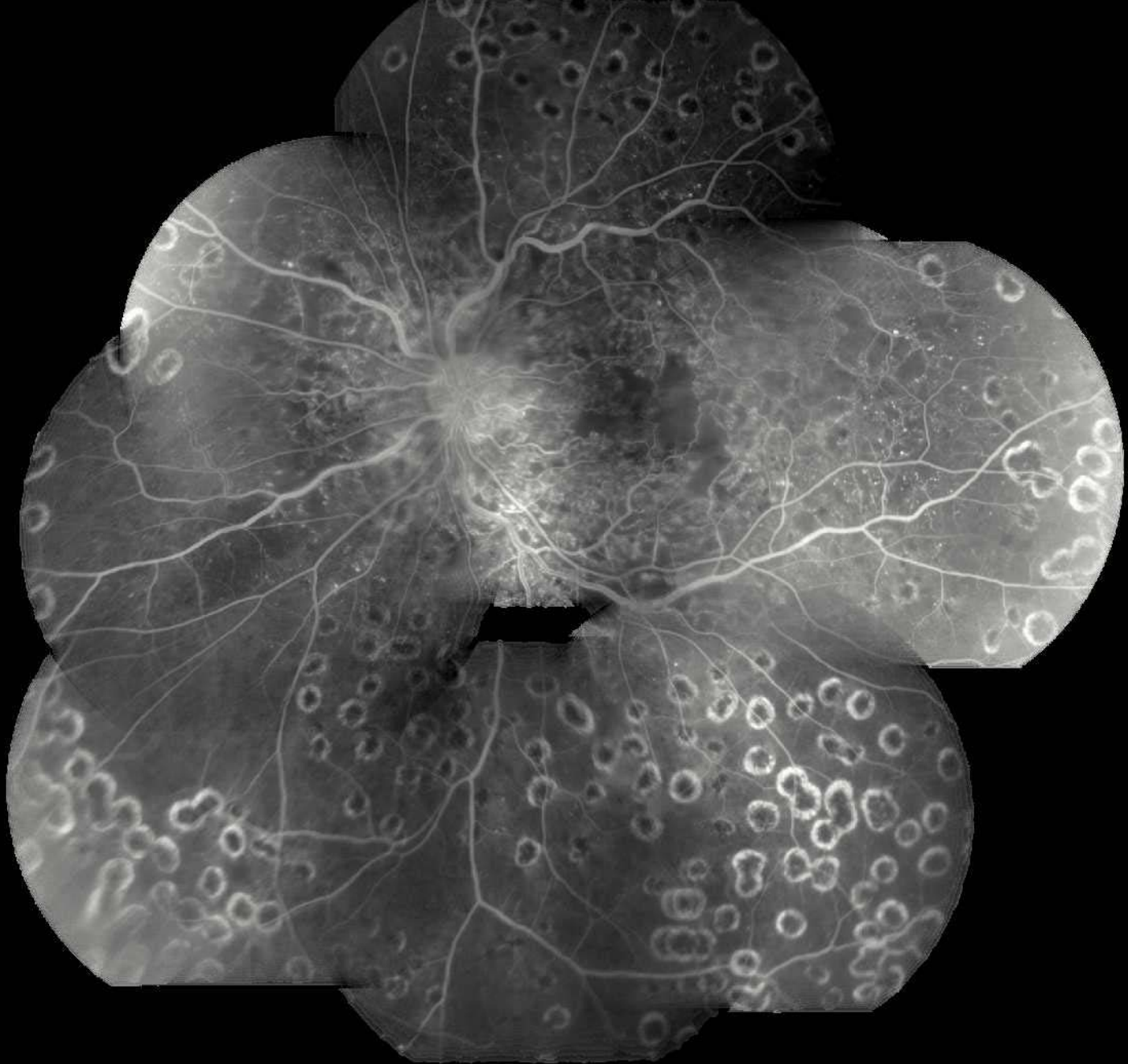
- Nov. 1992: RE ocular trauma with sympathetic ophthalmitis in LE -> enucleation RE
- Therapie: Decortin, Sandimmun
- Nov. 1997: first consultation in our surgery
- Change of therapy, because she wants a baby
- Deterioration of the ophthalmitis
  - > ozone-Therapy (till today 100x)
  - > now stabil

# Pat. Wolfgang M., geb. 1955

- Psoriasis with severe blepharitis and corneal ulcers
- „große Eigenblutbehandlung“ and ozone-water in the acute stadium, add. treatment with antibiotic ointment
- So far 3 relapses; after 6-7 sessions without symptoms







# Pat. Renate S., geb. 1956

- Diab.mell.-disposition in the family
- Diabetes since 1992
- 1996 no RD
- 1999 bil. PDVR
- 4/99-5/00 bil. Argon-Laser
- since 2/00 30 x ozone  
20 x Chelat  
30 x acupuncture

# Pat. Renate S., geb. 1956

- Progress of visual acuity:
- 7/96 RA: 20/20 LA: 20/20
- 4/99 20/20 20/50
- 1/00 20/70 20/200
- Start of ozone therapie
- 3/00 20/50 20/125
- 1/01 20/40 20/100

# Pat. Peter B., geb. 1941

- D.m. since 1996
- 1998 bilat. Argon-Laser with PDVR
- RE: vitreous haemorrhage,  
sec.glaucoma, Cat. complicata
- Visual acuity RE: NPL LA: 20/20
- Consultation in our surgery 11/98
- Over 10 months: 100 x ozone
- 3/00 LE PPV -> Visus acuity is stabil

# Example of progress in diab. retinopathy

